

SPINAL AXIAL TORQUE IN ADOLESCENT IDIOPATHIC SCOLIOSIS BEFORE AND AFTER SURGICAL CORRECTION

Tristan Langlais (1,2), Xavier du Cluzel (3), Nicolas Mainard (4), Samuel George (3), Laurent Gajny (1), Jean Dubouset (1), Raphael Vialle (4), Wafa Skalli (1), Claudio Vergari (1)

1. ENSAM, IBHGC-Institut de Biomécanique Humaine Georges Charpak, Paris, France ;
2. Département Orthopédie Pédiatrique, Hôpital des enfants, Purpan, Toulouse, France
3. Département Orthopédie Pédiatrique, Hôpital Necker Enfants Malades, APHP, UPC, Paris, France;
4. Department of Pediatric Orthopedic surgery, Armand Trousseau Hospital, APHP, Sorbonne University, Paris, France

Introduction

The study of the distribution of mass in adolescent idiopathic scoliotic (AIS) patients has shown promising preliminary results. This method was initially developed by Duval-Beaupère and Robain [1], and it allows to evaluate the loads applied to the spine by the overhanging mass. Recent advances in low-dose x-ray imaging and 3D reconstruction methods opened the way to wider use in clinic, and to the definition of novel biomarkers of severity and risk of progression in AIS. For instance, recent works showed that the axial torque at the junctional vertebrae (Figure 1) could play a role in the progression of the deformity [2,3].

The aim of this study was to analyze the spinal axial torque after surgical correction of severe scoliosis.

Methods

Twenty-nine AIS patients with an indication of surgery were included ($54 \pm 11^\circ$ Cobb angle, 15 ± 2 years old at surgery). Patients underwent biplanar x-rays in free-standing position before and at last follow-up (between 10 and 48 months). Their spine and external envelope were reconstructed with validated methods, while distribution of mass was estimated assuming typical density distributions [4]. Spinal axial torque was calculated with a previously described method [2], which consists in calculating the load applied to each vertebra by the overhanging mass (Figure 1). With certain orientations and displacement of the vertebra, this results in an axial torque.

Data collection was approved by an ethical committee (CPP IDF IV: 14409). Results were reported as average \pm standard deviation.

Results

The surgical procedure decreased the Cobb angle by $36^\circ \pm 11^\circ$. Table 1 reports spinal axial torque at specific vertebral levels.

Stage	Upper end	Apex	Lower end
Preop [N/m]	4.6 ± 2	1.6 ± 1.2	3.0 ± 1.7
Postop [N/m]	2.8 ± 1.3	1.0 ± 1.0	0.7 ± 0.5

Table 1: Axial torque pre- and post-operatively.

Postoperative decrease was significant at all vertebral levels ($p < 0.01$), and preoperative values were significantly different between levels ($p < 0.05$). Compared to 95th percentile of torque which was previously evaluated in asymptomatic subjects [3], more than 90% of patients had higher values at the upper and lower end vertebrae. Postoperatively, 62% of patients still had higher torque at the upper end vertebra than asymptomatic subjects, while only 38 % patients showed abnormal values at the lower junction.

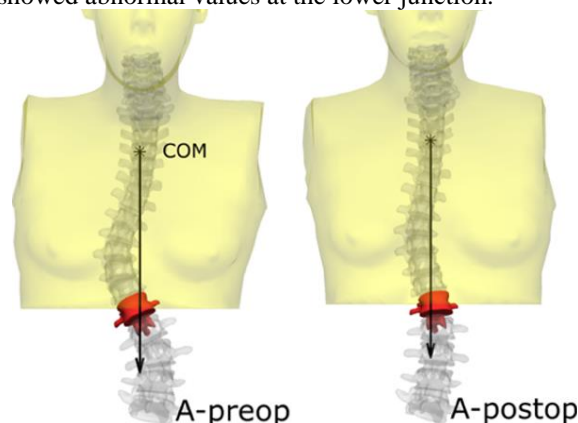


Figure 1: Spinal axial torque applied to the lower end vertebra by the trunk mass, before and after surgery.

Discussion

Biplanar x-rays and 3D reconstruction are now well established to study skeletal morphology and alignment in weight bearing position. Only recently, methods have been developed to study mass distribution.

Results of this study confirm that AIS patients show abnormally high spinal axial torque, especially at the end vertebrae, and that this parameter is normalized postoperatively for only a small number of patients. This further confirms that the axial plane plays an essential role in scoliosis. Further studies should focus on the relationship between this parameter and the development of postoperative mechanical complications.

References

1. Duval-Beaupère & Robain, Int Orthop, 11261-9, 1987.
2. Thenard et al, Spine deformity, 7:525-532, 2019.
3. Langlais et al, Med Eng & Phys 94:33-40, 2021.
4. Amabile et al., J Biomech 49:1162-1169, 2016.

